

# Metacarpophalangeal Joint Arthritis

The largest joints of the hand are called the metacarpophalangeal joints (MP joints). A joint is where two bones meet and move. The different joints of the hand are shown in Figure 1. MP joints are important for both power grip and pinch activities.

Arthritis is the wearing away of the cartilage at a joint. Cartilage is the coating layer of tissue on the end of a bone that acts as a shock-absorber. Loss of cartilage can lead to joint destruction and a shift in the finger position towards the small finger side, which is called ulnar drift (See Figure 2). When arthritis affects the MP joints, the condition is called MP joint arthritis.

## Causes

The MP joints are often affected by arthritis either from routine wear and tear, an injury, or medical conditions.

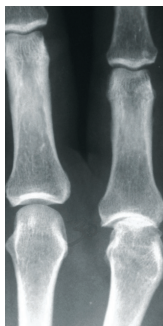The most common medical condition causing arthritis at the joint is termed rheumatoid arthritis. Rheumatoid arthritis affects the inner coating of the joint, called the synovium, and can result in the loss of the cartilage between the joints. The cause of rheumatoid arthritis is not known.

Other conditions that can cause loss of the cartilage include previous injuries and other medical conditions such as gout, psoriasis, or infection.

## Diagnosis

Arthritis may cause pain, loss of motion, swelling, and a joint that appears larger than normal. Also, especially in MP joint arthritis, the fingers can shift (See Figure 2). Pain in the joint is made worse by hard use of the hand in gripping and grasping activities. People with arthritis may notice weakness when trying to use their hands.

The diagnosis of arthritis is confirmed by taking x-rays. Figure 3 is an x-ray of a hand with arthritis: the x-ray shows narrowing of the space between the bones, which is a sign that cartilage has been lost.



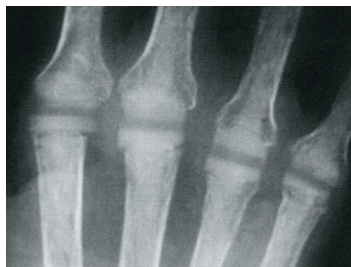**Figure 3:** X-ray of MP joint arthritis. The joint on the right has no space between the bones when compared to the joint on the left because of cartilage loss

## Treatment

There are many treatments available depending on the amount of pain and loss of function. Medication (prescribed by an arthritis doctor or rheumatologist) can be very helpful in relieving pain and preventing worsening joint destruction. Sometimes joint injections of a steroid medication can also help.

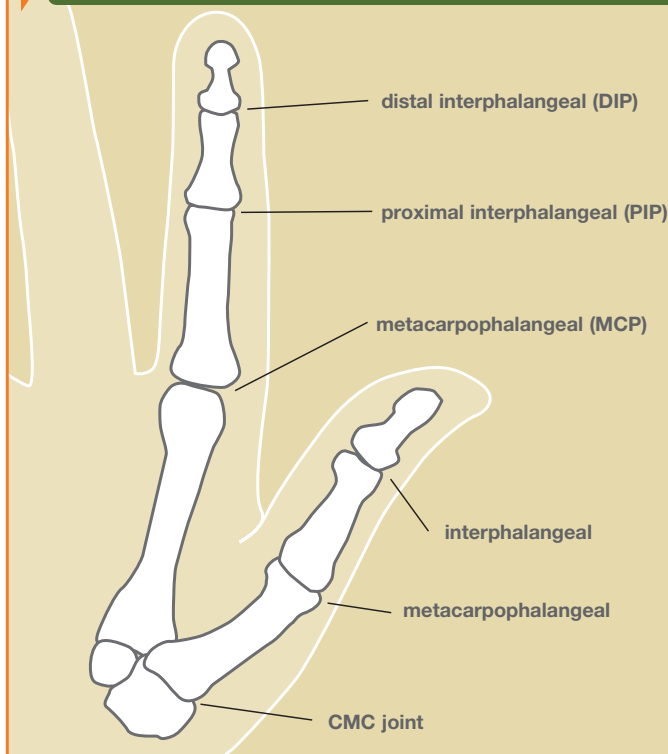
If medical treatment fails, then surgery can be considered. There are many surgical options. One option is synovectomy, which is the removal of destructive tissue. Also, since this disease can cause loosening of the tissues around the joint, these tissues can sometimes be tightened to provide relief.

If the joint is completely destroyed, then joint replacement or joint fusion are effective surgical options. The joints can be replaced with

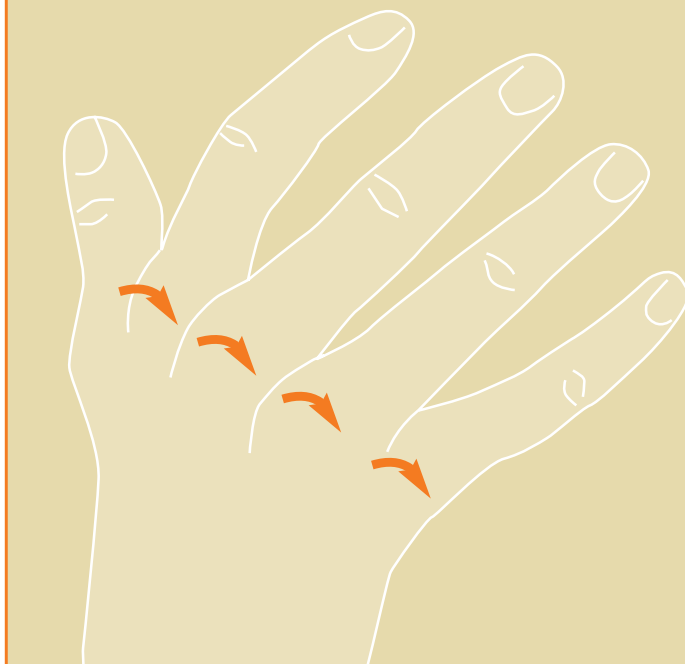

**Figure 4:** X-ray of silastic finger joint replacements

**Figure 1:** Finger Joints



**Figure 2:** Ulnar drift (fingers point towards little finger side)



a silicone implant (silicone is a plastic like material; see Figure 4) or other material (metal, pyrocarbon). Joint replacement is very useful, especially for older or less active individuals. Fusion—or making the joint solid—is an effective treatment of thumb MP arthritis.

Problems can occur after any type of surgery, including infection, loosening, or breakage of the artificial joint. Research is continuing to try to improve joint replacement and reconstruction in the hand.